

'Current Surgical Options for Visual Rehabilitation in Keratoconus'

Friday 3 September 2010
Hotel Concorde Lafayette
Paris, France

Sponsors:





Introduction

Beyond Ultra-Violet Crosslinking (UV-CXL)

Jérôme C Vryghem

Ultra-violet Crosslinking (UV-CXL) has changed our approach to keratoconus (KC) management dramatically. Due to its stabilising effect on the conus it opens up possibilities to visually revalidate KC patients that do not tolerate contact lenses any more and makes grafting the ultimate technique that only should be applied if all other surgical techniques of visual revalidation have failed or are not an option any more (BCVA < 0.2, K max > 65 D, pachymetries < 400 μ).

The idea to organise an expert meeting in September 2010 in Paris before the ESCRS congress on the "Current Surgical Options for Visual Rehabilitation in Keratoconus" came up in exchanging ideas with a lot of KC experts. In doing this my mind was even more confused than before. Three options of Surgical Visual Revalidation (SVR) techniques are available: intrastromal corneal ring segments (ICRS), phakic IOLs (PIOL), and/or topography-guided PRK (TG-PRK). Most KC experts apply the technique they know best. Not a lot of these experts are offering the three techniques to their patients. A lot of questions have no clear answers: What are the parameters to determine the progression of a conus? Do we still need UV-CXL in older patients? How long after UV-CXL can we apply a SVR procedure? What SVR procedure to apply when? The articles in this supplement, written by top experts in the field, illustrate there is still no clear answer to these fundamental questions.

Together with Efehan Coskunseven I organised another expert meeting/brainstorming session during the ESCRS Winter meeting in Istanbul on 18 February 2011 to address these matters. Some conclusions: UV-CXL should be applied in all established KC patients younger than 20 years without documentation of progression of the conus; no SVR procedure should be applied earlier than six months after a UV-CXL; the posterior float as measured by elevation topography systems helps in the diagnosis of KC but can not be used as a parameter to establish the progression of the conus; the most valuable parameter in establishing the progression of KC is K max; the value of corneal hysteresis in the diagnosis of KC is questionable; there is still no clear answer as to what technique to apply when; KC surgeons should be able to apply all of these SVR techniques.

Another expert meeting is scheduled to take place in September 2011.

Corneal biomechanics and choice of surgical technique for visual rehabilitation in keratoconus

Michael Mrochen

Knowledge of corneal biomechanics is helpful for understanding shape changes that occur in eyes with KC as well as their response to various surgical interventions. The latter information can be useful to surgeons in guiding decisions on a technique for visual rehabilitation, said Michael Mrochen PhD.

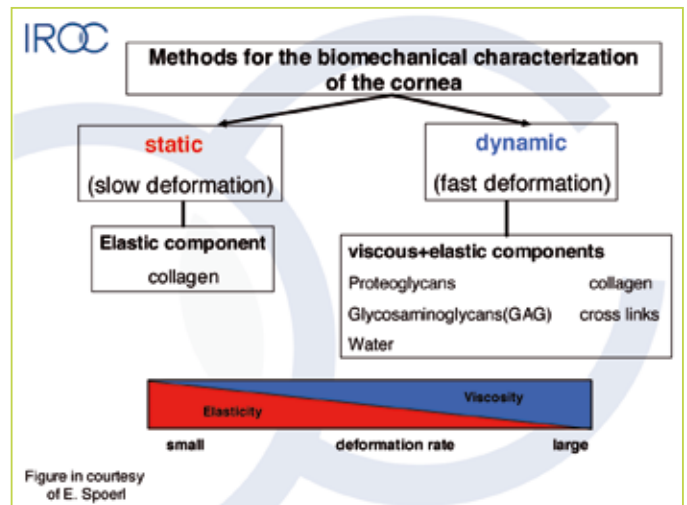
The cornea is a viscoelastic material, and in KC, both the elastic and viscous components of the cornea are reduced secondary to changes in the corneal collagen fibres and the ground substance (proteoglycans and glycosaminoglycans), respectively.¹ As a result of the altered biomechanics, tangential stress exerted by IOP on the collagen fibres results in the localised shape change that is characteristic of KC.

Surgical interventions can have biomechanical consequences both by redistributing stress and affecting the rigidity of the cornea. These effects can result in both immediate and delayed shape changes that affect visual performance and have implications for outcome stability. Since corneal rigidity is greater anteriorly than posteriorly and in the periphery versus centrally², different surgical procedures can have a different biomechanical impact depending on what region and layers of the cornea are affected.

However, it also must be taken into account that the keratoconic cornea responds differently to surgical procedures than a normal eye and that corneal biomechanics is age-related such that the elastic component increases and the viscoelastic component decreases with increasing age³, said Dr Mrochen.

Based on a review of the impact of different surgical interventions on corneal rigidity and optical aberrations and their refractive predictability and stability, Dr Mrochen summarised the potential role of combining the various procedures with crosslinking in eyes with KC.

Keratotomy procedures should not be performed except in rare situations and thermal collagen shrinkage has a questionable role because of limited stability of the refractive outcome. Intracorneal ring segment implantation with crosslinking may be a good solution, but suffers from limited refractive predictability, whereas the triple combination of crosslinking with excimer laser treatment to regularise the corneal shape and IOL implantation to optimise the refraction may allow good visual rehabilitation with high predictability of the refractive outcome.



"In combining any refractive procedure with crosslinking, we must also consider the refractive effects of the crosslinking treatment. Typically keratoconus eyes experience 1 to 2 D of flattening, and there may also be a significant myopic shift due to the redistribution of the steep cone towards the centre of the cornea," said Dr Mrochen.

References

1. Gefen A. Biochemical analysis of the keratoconic cornea. *J Mech Behav Biomed Mater* 2009 ;2 :224-236.
2. Dawson DG, et al. Biomechanical and wound healing characteristics of corneas after excimer laser keratorefractive surgery: is there a difference between advanced surface ablation and sub-Bowman's keratomileusis? *J Refract Surg* 2008;24 :S90-6.
3. Elseikh. Assessment of corneal biomechanical properties and their variation with age. *Curr Eye Res* 2007;32 :11-19.



UV-CXL in the future

Theo Seiler

As cornea surgeons look ahead to the future of collagen crosslinking (CXL) and refining the treatment protocol in order to optimise efficacy and safety, there are a number of issues under investigation. However, results from research conducted so far show that simple rules do not apply when trying to modify the treatment parameters. Therefore, until good outcomes data are available, including biomechanical measurements, any departure from standard treatment protocols should be undertaken very carefully, said Theo Seiler MD, PhD.

Three physical treatment parameters affect the outcome of CXL: 1) local tissue concentration of riboflavin, 2) UVA radiation fluence, and 3) interaction time, and studies investigating each of these factors show they are not linearly related to the post-CXL change in corneal elasticity. For example, when applying riboflavin to a de-epithelialised cornea, increasing the concentration from 0.1 per cent to 0.5 per cent does not result in five-fold increase in Young's modulus.

Regarding interaction time, there is a linear relationship between the change in the elasticity modulus and UVA exposure times between 15 and 45 minutes, but not for exposure times outside of that range. For

UVA fluence, the greater the increase, the less the additional effect is. For example, achieving a doubling of the elasticity modulus requires tripling of the UVA intensity, said Dr Seiler.

Data reported by A John Kanellopoulos MD, showing that the currently available UVA CXL lamps do not deliver a homogenous light profile onto the cornea has also raised questions deserving further research. Although the greatest crosslinking effect is achieved in the centre of the cornea where the UVA exposure is greatest, the cone may be located outside of this region. Determining whether or not outcomes can be improved by using a different light profile requires further study. However, it also remains unknown how much of a crosslinking effect is needed to achieve a successful clinical outcome.

"The failure rate with current treatment protocols is only three per cent, and so perhaps the amount of crosslinking could be reduced by a factor of two. We won't know until we have the data," said Dr Seiler.



Surgical rehabilitation techniques for keratoconus

Jérôme C Vryghem

Corneal collagen crosslinking (CXL) is an effective treatment for stabilising the cornea in eyes with keratoconus (KC), but in 2011, the refractive KC surgeon should be able to offer intrastromal corneal ring segments (ICRS), phakic IOLs (PIOL), and topography-guided PRK (TG-PRK) in order to meet patient demands for visual rehabilitation, said Jerome Vryghem MD.

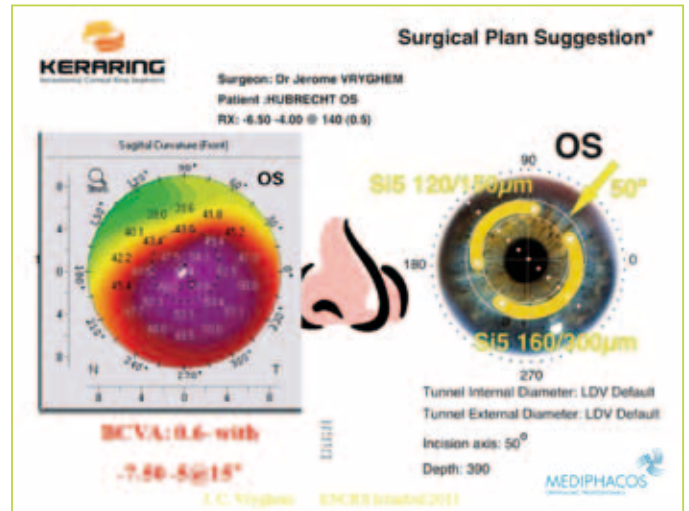
“We have achieved encouraging results performing all of these surgical procedures to improve visual function. However, patients must also be counselled to have appropriate outcome expectations so that they realise the quality of their vision will not be as good as with a hard contact lens,” he commented.

Reviewing his personal experience, Dr Vryghem stated he has been performing iris-claw phakic IOL implantation (Artisan, Ophtec) since 1991, TG-PRK using the WaveLight excimer laser platform (now Alcon Laboratories) since 2003, and ICRS implantation with Kerarings (Mediphacos) and femtosecond laser tunnelisation (Ziemer) for only one year. He presented results from analyses of data for 19 eyes treated with TG-PRK, 14 eyes implanted with a spherical or toric iris-claw PIOL, and eight eyes that had ICRS implantation. All eyes that had TG-PRK and some eyes in the other groups also underwent CXL, and the majority of eyes had follow-up for at least six months.

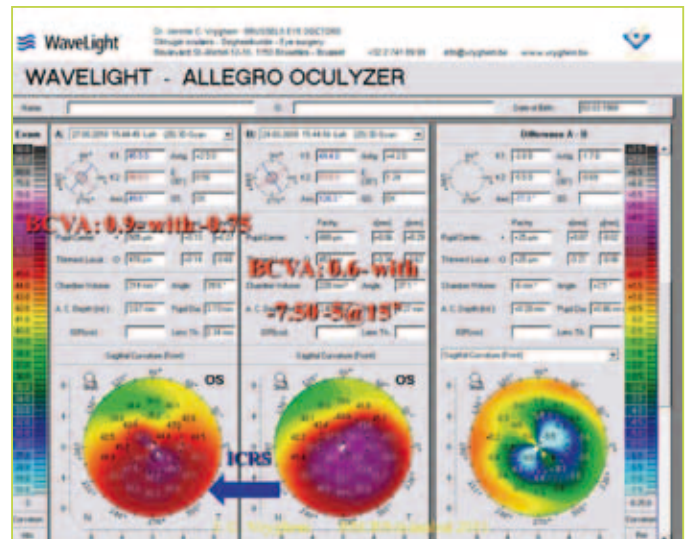
Overall, PIOL implantation afforded the best correction of higher ametropias and resulted in the highest independence from glasses or contact lenses with the fewest side effects. Patient satisfaction rates were also high even though the procedure does not regularise the cornea, noted Dr Vryghem.

He reported TG-PRK was associated with more frequent side effects and lower patient satisfaction, perhaps because the treated eye is more in competition with the better, non-treated eye. By removing tissue, this technique also has the drawback of limiting the possibility of retreatment. ICRS implantation enables recentring of the conus but was less effective in achieving emmetropia. Haloes were common although not always disturbing; six of seven patients were satisfied after this procedure.

Considering these outcomes and his ambitious goal to obtain near emmetropia, Dr Vryghem stated he has a slight preference for performing PIOL implantation for visual rehabilitation in KC, particularly in eyes with a good preoperative BCVA with a centred conus, higher myopia and astigmatism. TG-PRK may then be performed in a second-stage procedure if fine-tuning of the refractive outcome is needed or can be considered to treat low SE or astigmatism, but always in combination with CXL. ICRS implantation is another option for eyes with a decentred conus, higher myopia and/or astigmatism and mixed astigmatism, but should be performed with recognition that haloes are likely despite regularisation of the cornea.



Implantation of ICRS in a case with a lower BCVA and moderately decentred conus



Implantation of PIOL in a case with a good BCVA and centred conus



The Athens Protocol (Topography-guided PRK and CXL) vs. ICRS

A John Kanellopoulos

The Athens Protocol: Same day combined topography-guided partial PRK (TG-PRK) and corneal collagen crosslinking (CXL) is safe and effective for improving visual function in eyes with keratoconus (KC)¹⁻³ and ectasia after LASIK⁴ and preventing further disease progression, said A John Kanellopoulos MD.

The PRK procedure is performed to improve BSCVA and the biomechanical behavior of the ectatic cornea, by normalising the corneal surface and is done using the topography-guided platform of Allegretto excimer laser (Alcon Laboratories) with guidance from topographic imaging (Placido disc topography and/or Pentacam tomography). The ablation is designed to flatten some of the cone apex but also treats an arcuate (hyperopic-like) broader area away from the cone (usually in the superonasal periphery) that produces some elevation adjacent to the cone. The treatment plan can be visualised in Figure 1 below.

The procedure is performed using a 5.5mm optical zone and aims to treat up to 70 per cent of cylinder and 70 per cent of sphere with removal of no more than 50 microns of stroma. Mitomycin 0.02 per cent is applied for 20 seconds intraoperatively.

Pre- and post-treatment topographies of the Athens Protocol applied for ectasia are seen in Figure 2 above.

"We are frugal with the amount of tissue removed because these eyes have thin corneas. Considering the average thickness is about 450 microns, we have set 50 microns as an arbitrary ablation limit to comply with the 400 micron minimum thickness criteria for CXL," said Dr Kanellopoulos.

"Treating an area away from the cone and using a small optical zone help to minimise tissue removal, although the small optical zone can result in night vision symptoms."

Patients may experience significant pain after the procedure and are treated with antibiotic and cortisone drops, and a bandage contact lens. In a series of about 1,200 cases, there have been just a few eyes that developed significant scarring, delayed epithelial healing was encountered in some cases and treated with lubrication and homologous serum.

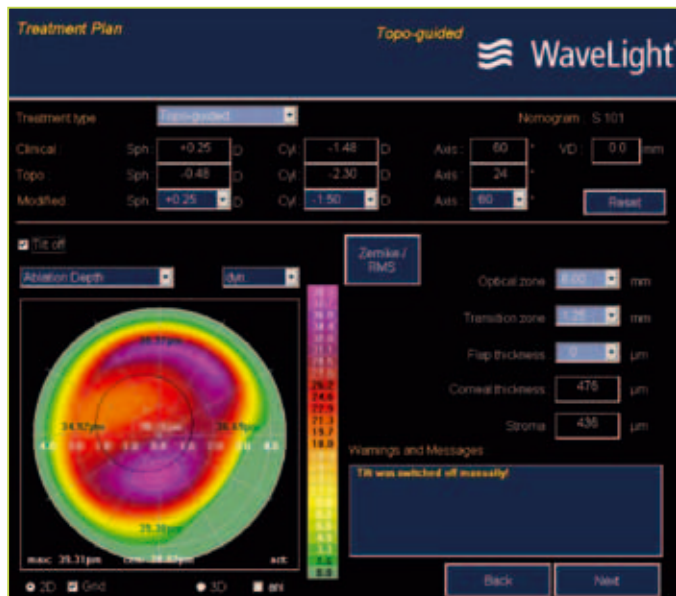


Figure 1

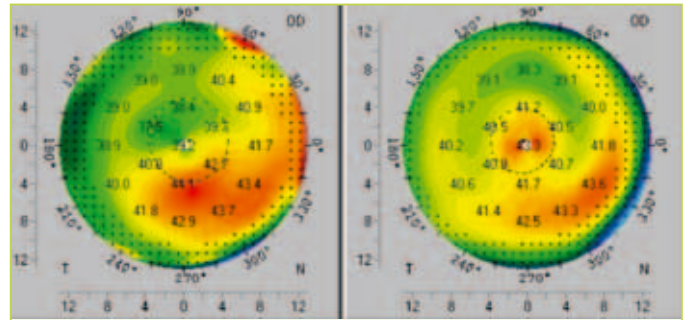


Figure 2

Dr Kanellopoulos noted he implanted intracorneal ring segments (ICRS; Intacs, Addition Technology) for visual rehabilitation in eyes with KC for several years. Using a nomogram that was a modification of the technique described by Joseph Colin MD, the results were favourable in terms of topographic, refractive, and visual acuity improvements. However, complications were common, including intrastromal deposits, ICRS extrusion, and infections.⁵

"I believe continued corneal thinning may account for some of the problems, and while most patients did not want to undergo explantation because they enjoyed great visual rehabilitation, they were treated successfully by ICRS removal followed by the Athens Protocol (CXL and TG-PRK)," said Dr Kanellopoulos.

He mentioned that results from early experience using an infrared continuous wave laser (Seros Medical) to shrink the anterior stroma followed by epithelium-on CXL are also encouraging. The novel, minimally invasive laser, which appears to have no effect on the epithelium, may be used to flatten the cone without any tissue removal. In an initial case, a 6 D flattening effect was achieved with no regression during follow-up to eight months, Dr Kanellopoulos reported.

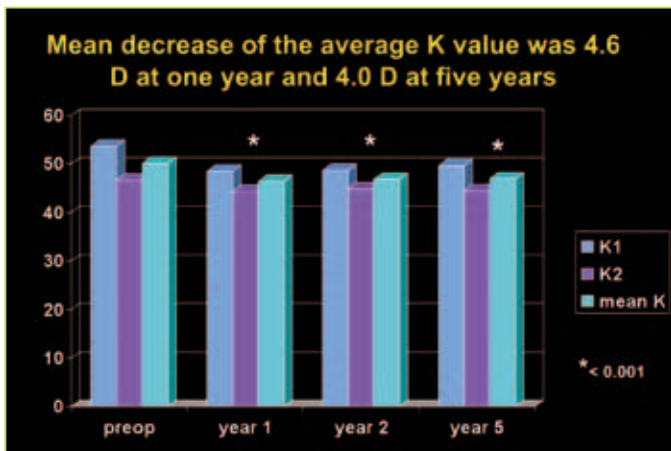
References:

1. Collagen cross-linking (CCL) with sequential topography-guided PRK: a temporizing alternative for keratoconus to penetrating keratoplasty. Kanellopoulos AJ, Binder PS. *Cornea*. 2007 Aug;26(7):891-5.
2. Comparison of sequential vs same-day simultaneous collagen cross-linking and topography-guided PRK for treatment of keratoconus. Kanellopoulos AJ. *J Refract Surg*. 2009 Sep;25(9):S812-8. doi: 10.3928/1081597X-20090813-10.
3. Stability of simultaneous topography-guided photorefractive keratectomy and riboflavin/UVA cross-linking for progressive keratoconus: case reports. Krueger RR, Kanellopoulos AJ. *J Refract Surg*. 2010 Oct;26(10):S827-32. doi: 10.3928/1081597X-20100921-11
4. Management of Corneal Ectasia After LASIK with Combined, Same-Day, Topography-Guided Partial Transepithelial PRK and Collagen Cross-Linking: The Athens Protocol. Kanellopoulos AJ, Binder PS. *J Refract Surg*. 2010 Nov 5:1-9. doi: 10.3928/1081597X-20101105-0
5. Modified intracorneal ring segment implantations (INTACS) for the management of moderate to advanced keratoconus: efficacy and complications. Kanellopoulos AJ, Pe LH, Perry HD, Donnenfeld ED. *Cornea*. 2006 Jan;25(1):29-33.



Stabilisation with ICRS implantation

Joseph Colin



Implantation of intracorneal ring segments (ICRS) is a valuable adjunct in the visual rehabilitation of keratoconus (KC), said Joseph Colin MD. "It is well-recognised that collagen crosslinking (CXL) is a wonderful tool for stopping KC progression. However, our data from five years of follow-up shows that progression was also stopped in almost 90 per cent of eyes after ICRS implantation with Intacs (Addition Technology)," said Dr Colin. His analyses included data from 105 eyes of 82 patients (mean age 30) that had implantation of one or two Intacs segments between 2000 and 2005 (prior

to availability of Intacs SK). All eyes were contact lens intolerant and had been referred for corneal transplantation; about half of the eyes had grade III KC. An unsatisfactory result was achieved in 12 eyes, most of which had a K value >55 D and/or central corneal thickness <350 microns, and eight of those eyes went on to keratoplasty. Intacs extrusion occurred in two eyes, but of the remaining 91 cases, only eight (8.8 per cent) showed progression of the cone by more than 1 D during five years of follow-up. Prior to Intacs implantation, cone progression by more than 1 D/year was observed in 59 per cent of the 105 eyes. "Even though KC may stabilise without any intervention, we were impressed by these results," said Dr Colin.

Between baseline and one year, mean MRSE decreased from -7.6 D to -3.86 D, mean BSCVA improved from 0.34 to 0.49, and mean average K decreased by 4.6 D. All of these improvements were generally maintained to five years when there was an average one line gain in UCVA.

Dr Colin also presented results for 34 eyes that underwent simultaneous ICRS implantation and CXL. Compared with the group that had ICRS implantation alone, there were no major differences with respect to BCVA, UCVA, MRSE, or keratometry outcomes.

Noting that both Intacs implantation and CXL have advantages and disadvantages, Dr Colin said that for patients who are younger and contact lens intolerant, he currently recommends ICRS implantation alone if the KC is stable and combined with CXL if the KC is progressing. For older contact lens intolerant patients with stable disease he prefers removing the crystalline lens and implanting a toric IOL.



ICRS implantation

Béatrice Cochener

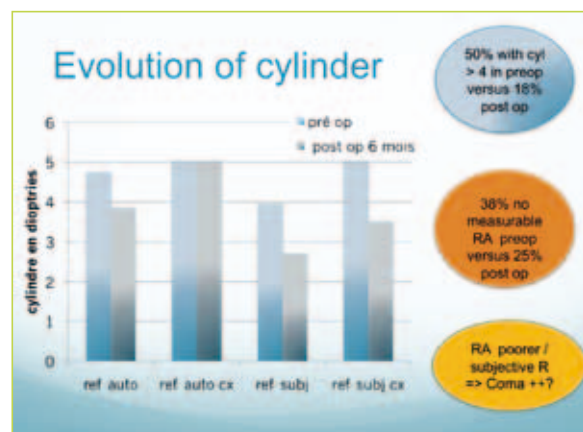
Implantation of intracorneal ring segments (ICRS) offers an effective method for visual rehabilitation in eyes with keratoconus (KC) that can be used alone or in combination with other modalities, said Béatrice Cochener MD. "ICRS implantation is reversible, so it is always worth trying. It can be used with cornea collagen crosslinking (CXL) and/or phakic IOL implantation as well after corneal transplantation if there is high irregular astigmatism," said Dr Cochener.

"When choosing ICRS for KC visual rehabilitation, surgeons need to keep in mind that the predictability is uncertain, but also that there should be no rush to combine procedures because mechanical changes take time."

Discussing her experience, Dr Cochener described Intacs SK (Addition Technology) as a "true advance" compared with the original design for improving visual outcomes and increasing the proportion of patients able to return to spectacle or contact lens wear. However, in eyes with significant astigmatism where myopia is only a minor component of the refractive error, she prefers the Keraring (Mediphacos) that offers greater astigmatic correction.

"Keraring implantation at a 6mm optical zone (SI-6 model) has become our first choice because it can correct up to 7 D of cylinder, as much as using the SI-5 model at a 5.0mm optical zone, but with better quality of vision," Dr Cochener said. She added she favours use of a femtosecond laser for creating the channels because it makes the surgery easier for the patient and surgeon and improves both safety and predictability.

Dr Cochener has also combined ICRS implantation with CXL in eyes with progressive KC if the pachymetry is at least 450 microns. Data from a series of 14 eyes of 7 patients that had simultaneous surgery showed that visual acuity continued to improve postoperatively for three months and the group benefited with greater reduction in cylinder compared with a control group of 28 eyes treated with CXL only. However, there was no difference between



groups in keratometry at three months, and pachymetry was stable after the combination procedure. "It was also interesting to me that refraction was not measurable preoperatively in 38 per cent of eyes versus in only 25 per cent after the ICRS procedure. I believe it is important to consider coma in patients without measurable refraction and we are now planning ICRS surgery according to the coma map," she said.

Phakic IOLs can also be combined with ICRS implantation although the ICRS procedure should be performed first if refraction cannot be measured. Dr Cochener indicated she prefers the posterior chamber ICL (Staar Surgical) in eyes with KC because it is farther from the cornea than the iris-claw implant (Artisan/Artiflex, Ophtec).



Corneal intrastromal implantation surgery with the MyoRing

Albert Daxer

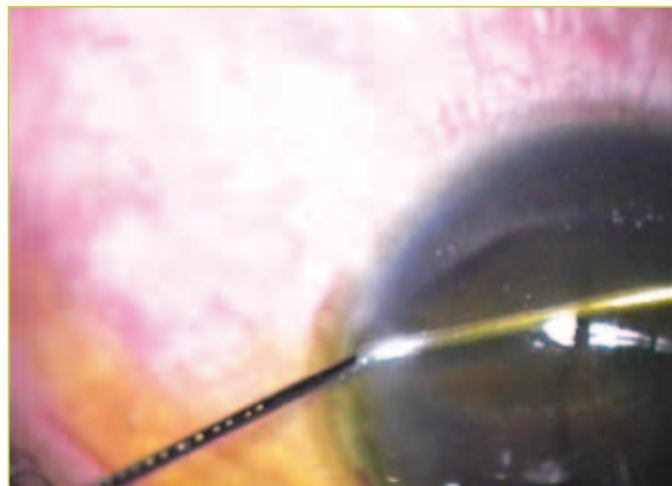
Corneal intrastromal implantation surgery (CISIS) is effective for regularising corneal shape in eyes with keratoconus (KC), including those with advanced stage disease, and in eyes with progressive KC, it can be combined with corneal collagen crosslinking (CXL) in a single session procedure that avoids the need for epithelial debridement, said Albert Daxer MD, PhD.

CISIS is performed using a particular microkeratome (PocketMaker, DiopTex) to create a closed, 9.0mm corneal pocket for insertion of a flexible, circular intrastromal corneal ring (MyoRing, DiopTex). The pocket is like an inverse flap and does not affect corneal biomechanical stability. It is created at a depth of 300 microns, and the ring is inserted via a small-incision tunnel that requires no suturing. Later adjustment of the ring position is possible because the pocket has a greater diameter than the implant.

"There is currently no method to predicting preoperatively the best position of an intracorneal implant for regularising corneal shape in eyes with KC. However, CISIS allows optimisation of the results by a simple post-implantation enhancement procedure to change the position of the ring. Moving the ring by just 0.5mm can produce a dramatic improvement in UCVA, BSCVA, and keratometry," said Dr Daxer.

Dr Daxer reported that in a cohort of eyes representing all grades of KC, CISIS was associated with an average two-line improvement in BSCVA, 8 D reduction in keratometry, and an average increase in UCVA by more than 8 lines.

The combination of CISIS and CXL in a single session is a four-step procedure. First the corneal pocket is created, and then riboflavin solution is injected into the pocket. After three minutes, UVA irradiation is delivered for 15 minutes, and then the MyoRing is implanted into the pocket.



Injection of riboflavin

"By preserving epithelium, this procedure is associated with better postoperative comfort and faster visual recovery than CXL with de-epithelialisation," said Dr Daxer.



Visual rehabilitation with the ICL

Jose F Alfonso

A combination surgical technique comprised of intracorneal ring segments (ICRS) to reduce corneal astigmatism, a phakic IOL (PIOL) to correct spherical error, and relaxing incisions to address residual astigmatism represents a safe and effective approach for refractive correction in eyes with keratoconus (KC), said Jose F Alfonso, MD.

"Five years ago we began performing PIOL implantation with the ICL (Staar Surgical) to correct refractive error in keratoconic eyes, and initially we achieved good results. However, the outcomes deteriorated as KC progressed over time. Therefore, our current preference is to first reduce as much astigmatism as possible using ICRS implantation with the Ferrara Ring

(International Medical Optics). Then, in a second step, residual refractive error is addressed using the ICL and relaxing incisions," explained Dr Alfonso.

"While the toric ICL can simultaneously correct sphere and cylinder, we prefer the spherical version to avoid introducing another confusing parameter."

A review of about 600 eyes that had undergone Ferrara ring implantation identified 49 with primary KC that subsequently received the ICL. KC eyes were eligible for ring implantation only if the corneal thickness was at least 400 microns. The rings were implanted at a 5mm zone and 80 per cent depth using a femtosecond laser for tunnelisation.

"The nomogram we used until 2008 allowed correction of 1 to 4 D of astigmatism based on five different ring combinations implanted at a 5mm optical zone and with the inferior height based on corneal pachymetry. The current nomogram offers eight possibilities, takes coma into account, and implants the ring segments at a 6mm optical zone and 70 per cent depth," he said.

Dr Alfonso reported results for 21 eyes that received the 90, 120, or 160 degree segments and had a minimum follow-up to one year. ICRS implantation based on the nomogram predictably reduced cylinder, and further correction of cylinder and sphere were achieved after ICL implantation with intraoperative relaxing incisions.

"The predictability of the SE outcome was excellent in these eyes, and improvements in both UCVA and BCVA were seen after each step of the surgery. A 1-line gain from preoperative BCVA occurred in 68 per cent of eyes after ICRS implantation and in 73 per cent after the second procedure," reported Dr Alfonso.

ICRS + ICL

YRS-AGE	F / ICL	Sphere	Cylinder	BCVA	Kerating / ICL
2007	OS	-15.00	-4.00 @ 90°	0.6	90° x 200 / 160° x 200
	OS	-13.00	-2.00 @ 90°	0.7	ICM 120v4 + RI
2008	OS	-0.75	-0.50 @ 90°	0.8	



ICRS implantation for visual rehabilitation

Maria-Clara Arbelaez

A study evaluating outcomes after implantation of intracorneal ring segments (ICRS) in eyes with keratoconus (KC) show that patients can benefit with better vision using either the Keraring (Mediphacos) or Intacs (Addition Technology), reported Maria-Clara Arbelaez, MD.

She presented results of a retrospective analysis of data from 83 eyes implanted with the Keraring and 18 eyes receiving Intacs. All eyes had clinically significant KC with loss of BCVA and contact lens intolerance. Implantation for both products was performed using the manufacturers' nomogram and a femtosecond laser for tunnel creation.

A total of 22 endpoints were evaluated for changes from baseline to follow-up at six months and included refractive parameters, corneal topography (Scout, Optikon), keratoconus indexes (Pentacam, Oculus), and corneal wavefront (Scout System) and ocular wavefront (Schwind System).

In the Keraring group, all variables showed significant improvement except for index of height asymmetry and posterior elevation apex, and 66 (79.5 per cent) eyes were considered to have a successful outcome based on achieving BCVA of 0.5 or better at six months (European legal limit for driving).

In the Intacs group, the success rate was not calculated because mean BCVA decreased, and only UCVA, sphere, average and Kmax, anterior elevation and three keratoconus indexes (RMIN, IVA, KI) showed statistically significant improvement.

"Although the Keraring procedure was associated with better outcomes for visual acuity, improvement in corneal topographic quality, and reduction of aberrations, it must be taken into account that there were a limited number of eyes in the Intacs group and that the procedure still resulted in improved UCVA and reduction in sphere and elevation," said Dr Arbelaez.

Analyses were also undertaken to identify predictors of BCVA success after Keraring implantation. Statistically significant associations were found for anterior elevation, posterior elevation, and Kmax at the apex as well as for CKI, RMIN, and corneal aberrations.

"Each of these variables offered only moderate predictive value and should not be used in isolation for patient selection. However, used collectively and with the clinical assessment, they can help guide selection of candidates for Keraring implantation," she said. "Overall, there is the potential for good outcomes in patients with mild to moderate KC."



Corneal biomechanical effects of ICRS implantation

Jorge Alio

In eyes with keratoconus (KC), information on corneal biomechanics can help to identify candidates for intracorneal ring segment (ICRS) implantation and predict the short-term visual outcome, said Jorge F Alio MD, PhD.

"ICRS implantation is safe and useful for remodeling the keratoconic cornea. However, the duration of the benefit varies and there are cases with similar preoperative topography and refraction in which implantation of the same ICRS generates a different outcome. Our interest has been to determine whether corneal biomechanics plays a role," said Dr Alio.

Initial research investigating corneal biomechanical properties in KC showed significant differences in corneal hysteresis (CH) and corneal resistance factor (CRF) values (ORA, Reichert) between keratoconic eyes and both normal controls and post-LASIK eyes.¹ Further study showed CRF was a much better index of KC severity than CH and that CRF was significantly correlated with keratometry and spherical-like aberrations.²

To investigate predictors of the ICRS effect in KC, data were analysed from 45 consecutive eyes of 35 patients implanted with Kerarings (Mediphacos). KC grade ranged from I to IV, but the majority had grade I or II disease (69 per cent).

Assessments at one month showed significant central flattening, highly significant decreases in total HOAs, primary coma, and coma-like RMS, and no significant changes in manifest sphere or cylinder. There was non-significant regression in all of the parameters at six months.

CH and CRF were unchanged at one month after surgery, but CH had increased significantly at three months and CRF decreased significantly at six months.

At all postoperative visits, corneal HOAs and coma correlated significantly with the preoperative CRF, but the HOA values were not related to the preoperative CH. A statistically significant correlation was also seen between the preoperative K value and postoperative visual outcome, but only at one month.

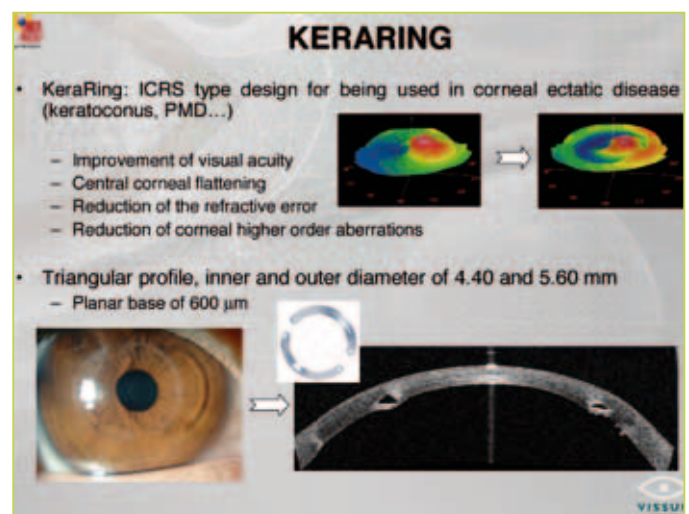
"From these data we developed a model incorporating refractive, corneal aberrometric, and corneal biomechanical data obtained with the ORA that accurately predicts postoperative BSCVA," said Dr Alio.

The research also suggests that the best keratoconic candidates for ICRS are patients with low mean keratometry and a small difference between CH and CRF values.

"As the difference between these two biomechanical parameters increases, both the magnitude and stability of the response to ICRS implantation decreases," said Dr Alio. This may be an important predictive factor for success of ICRS implantation and would eventually help for better selection of candidates for this type of surgery.

References:

1. Ortiz D, et al. Corneal biomechanical properties in normal, post-laser in situ keratomileusis, and keratoconic eyes. *J Cataract Refract Surg* 2007;33:1371-1375.
2. Pinero DP, et al. Corneal biomechanics, refraction, and corneal aberrometry in keratoconus: an integrated study. *Invest Ophthalmol Vis Sci* 2010;51:1948-1955.





Visual rehabilitation with toric IOLs in patients with cataract and keratoconus

Rudy Nuijts

Implantation of a pseudophakic toric IOL can be a useful option for visual rehabilitation in selected eyes with early keratoconus (KC) or pellucid marginal degeneration (PMD) requiring cataract surgery. However, in planning the surgery it is important to recognise that the surgery itself, even when performed through a small (2.2mm) incision, is likely to induce significantly more astigmatism than if performed in a normal eye, said Rudy Nuijts MD, PhD.

“Because these pathologic corneas respond differently to incisional surgery, it may be best to operate through a scleral incision to minimise surgically-induced astigmatism,” said Dr Nuijts.

Dr Nuijts noted that European surgeons have a number of pseudophakic toric IOL options to choose from, but that his experience is mostly with the AcrySof Toric IOL (SN60TT, Alcon Laboratories), which is available in seven models in 0.75 D cylinder steps that can correct 1.03 to 4.11 D of cylinder at the corneal plane.

Using this implant for visual rehabilitation in KC, he reported achieving 75 per cent to 80 per cent reduction of astigmatism accompanied by marked improvement in UCVA.¹

Dr Nuijts said the hydrophobic acrylic IOL unfolds slowly in the eye, which facilitates IOL positioning.

“It is easy to rotate this lens for alignment, even slightly in the counterclockwise direction if that is necessary,” he commented.

However, careful marking of the eye to guide precise orientation and meticulous removal of viscoelastic from behind the lens are critical for achieving accurate and stable results.

“Assuming adequate removal of viscoelastic, there is substantial evidence showing minimal postoperative rotation of this lens. A number of published studies report mean rotation of ≤ 3.5 degrees and rotation of ≥ 10 degrees in ≤ 4.5 per cent of eyes,” said Dr Nuijts.

Dr Nuijts presented three cases involving eyes of two patients, ages 64 and 78 years old, with diagnoses of PMD, PMD/KC, and forme fruste KC. Preoperative refractive cylinder ranged from -2.5 to -6.0 D, corneal astigmatism ranged from 2.1 to 4.1 D (Figure 1) and BCVA from 0.125 to 0.5. After implantation of the AcrySof toric IOL, refractive cylinder was reduced to -0.75 to -1.5 D. The IOL misalignment ranged from one to three degrees (Figure 2). The BCVA improved to between 0.5 and 0.8 D, UCVA ranged from 0.2 to 0.6, and both patients were satisfied with their outcomes.

Reference

1. Visser N, Gast STJM, Bauer NJC, Nuijts RMMA. Cataract surgery with toric intraocular lens implantation in keratoconus: a case-report. *Cornea* 2011; In Press.

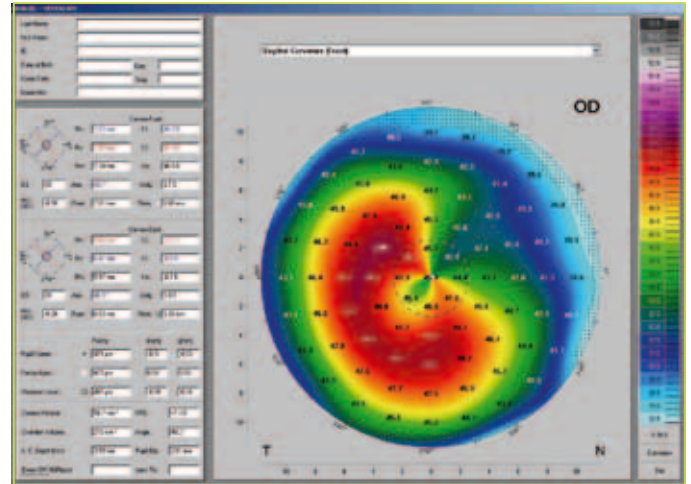


Figure 1 – Preoperative curvature map of the anterior corneal surface of a patient with Pellucid Marginal Degeneration

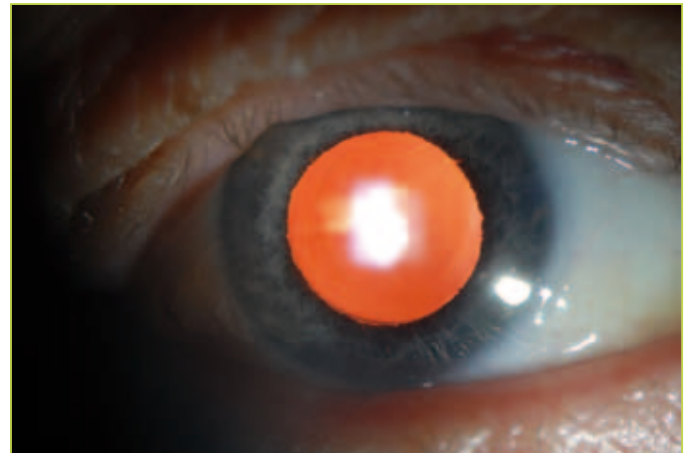
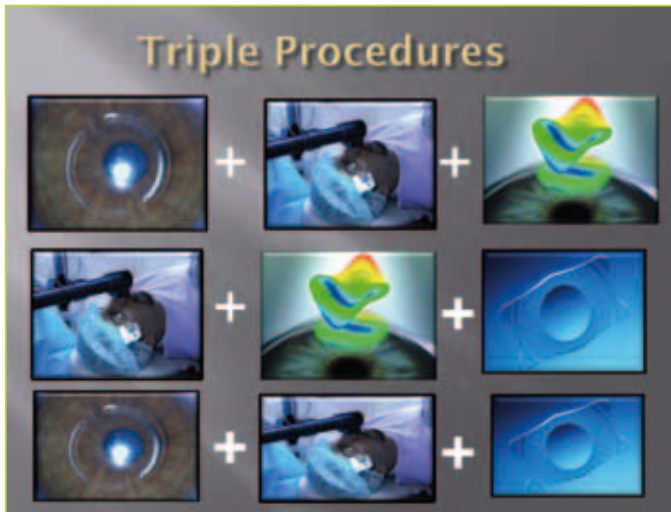


Figure 2 – Slit-lamp photograph of a patient with keratoconus and an AcrySof toric intraocular lens with a cylinder power of 6.0 D (implanted at nine degrees). Postoperatively, the IOL was aligned at seven degrees



Combination surgery for visual rehabilitation

Efeke Coskunseven



Intracorneal ring segment (ICRS) implantation with Kerarings (Mediphacos) followed by transepithelial topography-guided PRK and then corneal collagen crosslinking (CXL) appears to be an effective treatment sequence for halting disease progression and improving visual function in eyes with keratoconus (KC), said Efeke Coskunseven, MD.

"The combination of Keraring implantation and transepithelial topo-guided PRK (topo-PTK PRK) is more effective than either procedure alone for reducing astigmatism, while CXL appears to be safe and effective for stopping KC progression. Now longer term follow-up in a larger population is needed to validate our early encouraging findings," said Dr Coskunseven.

Dr Coskunseven uses the following criteria to select eyes for this triple procedure: KC grades 1-III, ≥18 years old, contact lens intolerance, and corneal thickness ≥400 microns at the intended site for tunnel creation. Eyes are excluded if the K value is >65 D, there is corneal dystrophy, hydrops, or keratitis, or if the patient is severely atopic or has some other significant systemic disease.

He presented results from 16 eyes of 10 patients that underwent the triple procedure. The mean interval between Keraring implantation and CXL was seven months, and the topo-PTK PRK was performed an average of 8.2 months after CXL. ICRS implantation was performed using a femtosecond laser for channel creation and the segments were inserted to a depth of 80 per cent based on the thinnest point. The corneal incision was performed at the steep axis. Topo-PTK PRK was performed with the Wavelight Allegretto 400 Hz laser (Alcon Laboratories) targeting about 80 per cent refractive correction with a maximum ablation of 50 microns using a 5.5mm optical zone and 9.0mm transition zone.

UCVA increased from 0.1 at baseline to 0.25 after ICRS implantation and continued to improve to 0.3 after CXL and to 0.58 after the topo-PTK PRK. Refractive cylinder similarly improved after each procedure, decreasing from -4.34 D to -0.98 D after topo-PTK PRK.

When we evaluate the difference between Kmax and Kmin in 3mm OZ; preoperatively was 11 D it decreased to 7.2 D after ICR implantation and it decreased to 6.5 D after CXL treatment and finally decreased to 1.1 D after Topo-PTK PRK. Total decreasing in difference between Kmax-Kmin in 3mm OZ was 9.9mm.

When we evaluate the MaxK in 3mm OZ; preoperatively was 56.7 it decreased to 49.3 D after ICR implantation and it decreased to 49.2 D after CXL treatment and finally decreased to 2.8 D after Topo-PTK PRK. Total decreasing in Max K was 10.3D.

ICRS implantation had the greatest effect on keratometry. Mean K decreased from 51.23 D to 48.05 D after ICRS implantation and decreased by about 1 D after both CXL and the PTK PRK.

"It is important to note, however, that the flat K value decreased only 1 D after ring implantation whereas the steep K value decreased about 5 D," said Dr Coskunseven

"Maximum Keraring effectiveness in dioptres according to corneal thickness is about 7 D. CXL to be a safe procedure that has shown to stop the progression of the keratoconus however effectiveness is maximum 1.5 D. Maximum ablation depth for Transepithelial Topo Guided laser treatment is 50 μ in 5.5mm OZ and the maximum effect can be about 5 D," said Dr Coskunseven

KeraRing ICR Implantation is an effective method for the improvement of UCVA and BCVA in keratoconic eyes .
Maximum Keraring effectiveness in dioptres according to corneal thickness is about 7 D.

Corneal Pachymetry Safety Limits Reference Table					
Processed Segment Thickness	150μm	200μm	250μm	300μm	350μm
Minimum Corneal Thickness Required (mm) (D)	250μm	335μm	420μm	500μm	580μm

<7 D Irregularity

Methods
However combination of both treatments will be more effective than ICR or Transepithelial Topo G.L.T alone

<7 D Irregularity

❖ Stop Progression
❖ <1,5D Irregularity

50 μ
5.5 mm
< 5 D



A personal decision tree for visual rehabilitation

Jose Güell

For Jose Güell MD, corneal collagen crosslinking (CXL), a toric phakic IOL (tPIOL), and intracorneal ring segments (ICRS) are the major surgical tools for visual rehabilitation of keratoconus (KC). Dr Güell explained he determines the need for these procedures based on a decision tree that takes into account disease progression and the level of irregular astigmatism.

"In our experience, a combination including CXL if needed for disease stabilisation with ICRS implantation to regularise the cornea if needed and in some cases a tPIOL for correcting residual ametropia is a novel and robust strategy for managing KC," said Dr Güell.

According to Dr Güell's algorithm, the level of irregular astigmatism is practically defined by the difference between the best-corrected visual acuity with a rigid gas permeable contact lens (BCVA) versus with spectacles (BSCVA). In eyes with clinically insignificant irregular astigmatism (BCVA = BSCVA), a tPIOL might be adequate for visual rehabilitation. In eyes with clinically significant irregular astigmatism (two-line difference between BCVA and BSCVA), ICRS implantation is performed first to regularise the cornea. Once the results are stable, a tPIOL might be implanted for refractive improvement.

CXL is added if KC is unstable and done after ICRS implantation and prior to the tPIOL procedure. As alternatives, PRK + CXL or topo-guided PRK + CXL can be performed in eyes with clinically insignificant and clinically significant irregular astigmatism, respectively. Taking into account the risk in ablating tissue in a KC eye and the lack of long-term information, we only consider the PRK combination in selected eyes with low ametropia

"However, in eyes with highly irregular astigmatism where the BCVA is much worse than the BSCVA, neither PRK nor ICRS implantation will likely be adequate to correct the astigmatism. Then, corneal transplantation is probably necessary, said Dr Güell.

"Some surgeons report good experience using smaller diameter rings in eyes with a lot of irregular astigmatism, but the cornea is likely very thin so that corneal transplantation (Deep Anterior Lamellar Keratoplasty) use to be really the best option."

Dr Güell said he prefers the toric foldable iris-claw phakic IOL (Artiflex, Ophtec) mostly based on 20 years of favourable experience with the iris-claw technology. He reported outcomes from three years of follow-up in 17 eyes implanted with this lens after CXL showing the combination was effective for improving vision and predictably decreased astigmatism. SE, cylinder, keratometry, and endothelial cell count values all remained stable. Distance UCVA was 20/40 or better in 94 per cent of eyes, and no eyes experienced any loss of distance CVA. Achieved SE was within 1 D of attempted in 94 per cent of eyes and within 0.5 D in 82 per cent. Refractive astigmatism was >1.50 D in all eyes preoperatively, and at three years was ≤ 1 D in 76 per cent of eyes and ≤ 0.50 D in 24 per cent.

Contacts:

Michael Mrochen
Email: michael.mrochen@iroc.ch

Theo Seiler
Email: theo.seiler@iroc.ch

Jerome C Vryghem
Email: Dr.J.C.Vryghem@vryghem.be

A John Kanellopoulos
Email: ajkmd@mac.com

Joseph Colin
Email: joseph.colin@chu-bordeaux.fr

Béatrice Cochener
Email: beatrice.cochener@ophtalmologie-chu29.fr

Albert Daxer
Email: daxer@gutsehen.at

Jose F Alfonso
Email: j.alfonso@fernandez-vega.com

Maria-Clara Arbelaez
Email: info@muscatye.com

Jorge Alio
Email: jlalio@vissum.com

Rudy Nuijts
Email: rudy.nuijts@mumc.nl

Efeken Coskunseven
Email: efekanc@gmail.com

Jose Güell
Email: guell@imo.es

